

Ruptured ileocolic artery pseudoaneurysm: case report

Pseudoaneurisma roto de artéria ileocólica: relato de caso

Carolina Vasconcellos Sant'Anna¹, Felipe Garcia Kuhl¹, Alane Miranda Leite¹, Selma Regina de Oliveira Raymundo¹ , André Rodrigo Miquelin¹, Vitória Acar¹, Vitor Brumato Fachini¹, Matheus Rafael Canuti¹

Abstract

Visceral artery aneurysms (VAAs) and visceral artery pseudoaneurysms (VAPAs) are rare conditions and are potentially lethal when they rupture. They are usually found as incidental findings on computed tomography (CT) scans of asymptomatic patients. Although conventional open surgery is currently considered the gold standard treatment, the endovascular approach has gained prominence as a minimally invasive procedure with lower surgical risk. In this approach, use of coil embolization in saccular VAAs and VAPAs and implantation of flow-modulating stents constitute alternative treatments for fusiform aneurysms. We present the case of a 51-year-old female patient complaining of acute abdominal pain, tachycardia, and hypotension, with evidence of abdominal bleeding on CT angiography, who was diagnosed with a ruptured ileocolic artery (ICA) pseudoaneurysm. She underwent early endovascular treatment for ICA embolization, which was successful and achieved clinical improvement.

Keywords: endovascular procedure; pseudoaneurysm; superior mesenteric artery.

Resumo

Os aneurismas de artérias viscerais (AAVs) e pseudoaneurismas de artérias viscerais (PAAVs) são condições raras e potencialmente letais quando rotos. Em geral, são encontrados incidentalmente na tomografia computadorizada de pacientes assintomáticos. Embora a cirurgia aberta convencional seja considerada atualmente o tratamento padrão ouro, a abordagem endovascular vem ganhando relevo por ser considerada um procedimento minimamente invasivo e com riscos cirúrgicos menores. Destaca-se, nessa abordagem, o uso de embolização por molas (*coils*) em AAVs e PAAVs saculares e implante de stent modulador de fluxo como alternativa de tratamento para aneurismas fusiformes. Apresentamos o caso de uma paciente de 51 anos com queixa de dor abdominal aguda, taquicardia e hipotensão, com evidência de sangramento abdominal em angiotomografia e diagnóstico de pseudoaneurisma de artéria ileocólica (AIC) roto. Ela foi submetida a tratamento endovascular precoce de embolização da AIC com sucesso, e houve melhora do quadro clínico.

Palavras-chave: procedimento endovascular; falso aneurisma; artéria mesentérica superior.

How to cite: Sant'Anna CV, Kuhl FG, Leite AM, et al. Ruptured ileocolic artery pseudoaneurysm: case report. J Vasc Bras. 2021;20:e20210163. <https://doi.org/10.1590/1677-5449.210163>

¹Faculdade de Medicina de São José do Rio Preto – FAMERP, São José do Rio Preto, SP, Brasil.

Financial support: None.

Conflicts of interest: No conflicts of interest declared concerning the publication of this article.

Submitted: August 23, 2021. Accepted: November 10, 2021.

The study was carried out at Hospital de Base pela Instituição Faculdade de Medicina de São José do Rio Preto (FAMERP), São José do Rio Preto, SP, Brazil.



Copyright© 2021 The authors. This is an Open Access article distributed under the terms of the Creative Commons Attribution License, which permits unrestricted use, distribution, and reproduction in any medium, provided the original work is properly cited.

■ INTRODUCTION

Visceral artery aneurysms (VAAs) and visceral artery pseudoaneurysms (VAPAs) are rare, with incidence in the range of 0.01 to 0.2%.¹ Technical developments in imaging exams for detecting intra-abdominal diseases, such as abdominal computed tomography angiography (angio-CT) and Doppler ultrasound (USD),^{2,3} and the increased frequency of manipulation of the biliary tract have led to increases in prevalence rates and incidental findings of aneurysms. While VAAs are primarily caused by hypertension, atherosclerosis, dysplasia, and connective tissue diseases, VAPAs are associated with traumas, iatrogenic injuries, and inflammation or infection.⁴ The splenic artery is the most often involved in aneurysms and pseudoaneurysms, followed by the hepatic artery, celiac trunk, and inferior mesenteric artery.⁵

Compared with true aneurysms, VAPAs more frequently involve the gastroduodenal and superior mesenteric arteries (SMA) and ruptured pseudoaneurysms of the SMA are associated with a 37% mortality rate.⁶

Aneurysms and pseudoaneurysms of the ileocolic arteries (ICA) are rare and generally asymptomatic, but when symptomatic they are associated with signs of rupture such as abdominal pains, lower intestinal bleeding, and intra-abdominal hemorrhage, or signs of hypovolemic shock.⁷ Conventional surgery is considered the gold standard treatment, but endovascular treatment (ET) is gaining acceptance, particularly for management of patients at high risk from surgery.^{8,9}

We present the case of a female patient diagnosed with a ruptured VAPA of the ICA who underwent successful ET. We highlight the importance of knowledge of this condition, which, while rare and potentially fatal, can also have a favorable outcome if diagnosed and treated early.

This study was approved by the Research Ethics Committee at our institution (CAAE: 50239621.8.0000.5415, consolidated opinion number: 4.919.534).

■ DESCRIPTION OF THE CASE

The patient was a 51-year-old female admitted via emergency because of intense upper abdominal pains with onset 2 days previously, progressive worsening, hour by hour, and no response to analgesics. At admission, her general condition was regular, with cutaneous-mucosal pallor, cold skin, blood pressure of 125 x 59 mmHg, heart rate of 116 bpm, respiratory rate of 17 breaths/min, and body temperature of 36.1°. On physical examination, her abdomen was flat, with mild pain on deep palpation of the superior region, no masses, and no pain on decompression.

Abdominal angio-CT was ordered, showing a large intraperitoneal hematoma in the mesogastric region measuring approximately 800 cm³ and presence of a moderate volume of free liquid in the abdominal cavity. The SMA was patent and a fusiform dilatation of the ICA was visible, with irregular outlines and contrast leakage to the right throughout its course (Figures 1A and 1B). The patient reported no history of prior disease and no continuous medication usage, but said she had undergone videolaparoscopic cholecystectomy several years previously.

The patient was transferred to the catheterization laboratory and underwent arteriography, using the Seldinger technique to fit a 5Fr Performa® hemostasis valve (Merit Medical Systems, Inc., Utah, United States) and position a Cobra Performa® catheter (Merit Medical Systems, Inc., Utah, United States), followed by injection of contrast, which showed the dilatation and contrast leakage from the ICA (Figures 2A and 2B). Selective catheterization of the ICA was performed with a Progreat microcatheter (Terumo Corporation, Tokyo, Japan) and the decision was taken to embolize this artery by releasing Axium Prime™ 2.5 x 6 cm microcoils (Medtronic, Dublin, Ireland) into the area at the termination of the dilatation and Axium™ 2.5 x 8 cm microcoils (Medtronic, Dublin, Ireland) to seal the outflow, followed by release of Nester® embolization coils (Cook Medical Inc., Indiana, United States) into the contrast leakage area (five 14 x 20 mm coils and two 14 x 18 mm coils), sealing the inflow (Figure 3). After the procedure, the patient reported improvement in pain and was hemodynamically stable. She was discharged from hospital on the 3rd postoperative day. At a 3-month follow-up, she was asymptomatic and control angio-CT showed no leakage or retroperitoneal hematoma (Figures 4A and 4B).

■ DISCUSSION

VAAs and VAPAs are rare manifestations, with incidence in the range of 0.1 to 2%,¹ but, despite their low incidence, they have a high rate of rupture (25%) with significant morbidity and mortality (70%).^{5,10} They are caused by a variety of etiologies and initial diagnosis can be achieved with USD and computed tomography (CT) with sensitivity of 50% and 67%, respectively. Angiography is the gold standard, because it enables more specific identification of location and confirmation of collateral flow and can also be used for treatment.¹¹ VAPAs of the SMA are most frequently caused by inflammation due to pancreatitis or other etiologies, but can also be caused by iatrogenic traumas⁶ during surgery or angiography or by accidents or penetrating traumas.¹¹ The increased frequency of manipulation of the biliary

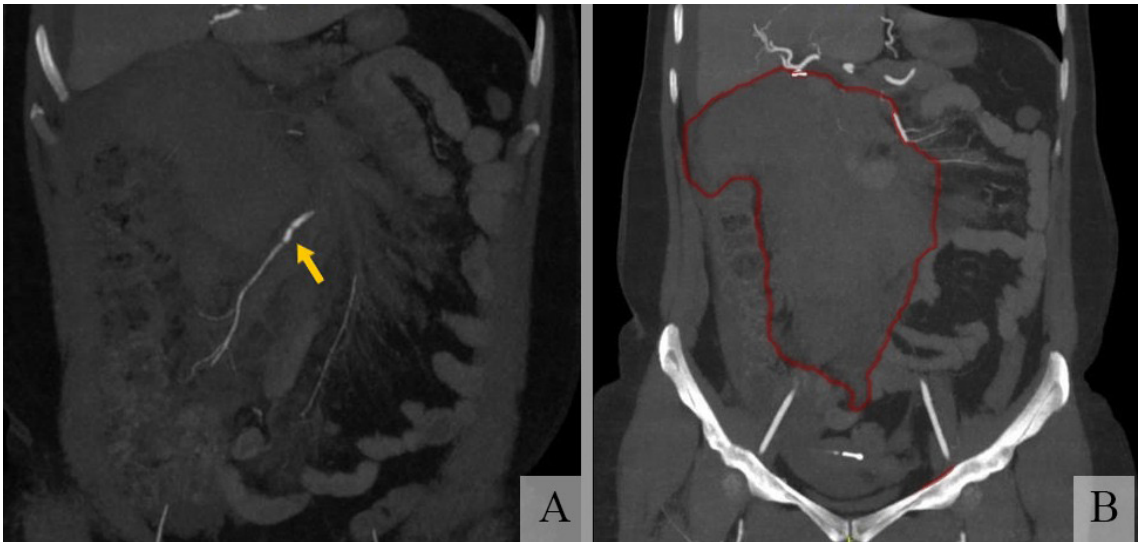


Figure 1. Abdominal angiotomography showing: **(A)** superior mesenteric artery with fusiform dilatation of the ileocolic artery, which has irregular borders and contrast leakage; **(B)** large intraperitoneal mesenteric hematoma and presence of free liquid in the abdominal cavity.

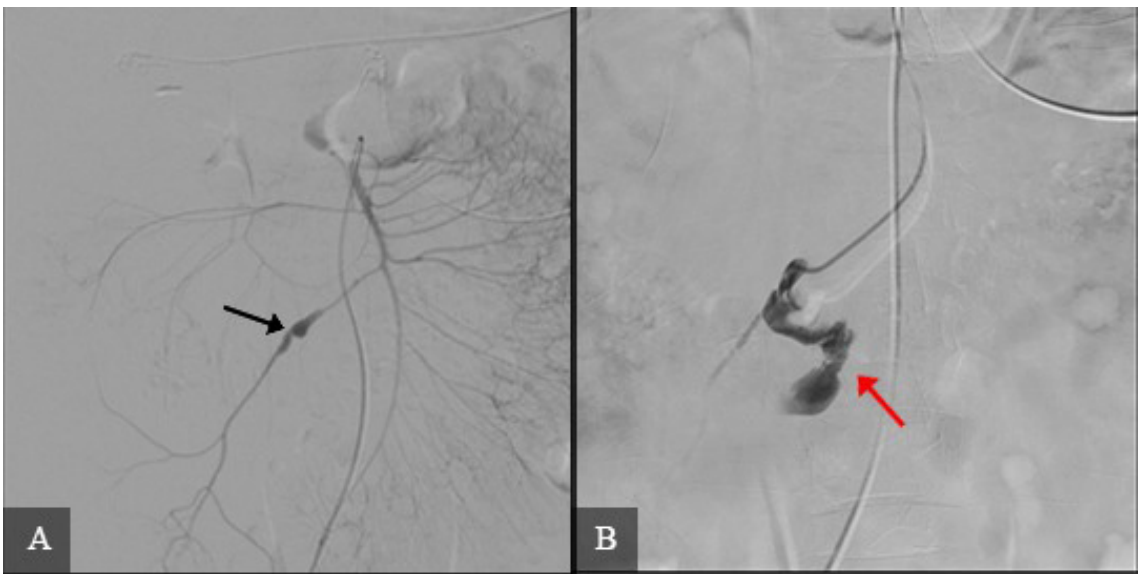


Figure 2. Angiography of the abdominal arteries showing: **(A)** fusiform pseudoaneurysm in the mid ileocolic artery (black arrow); **(B)** contrast leakage, indicative of rupture (red arrow).

tract with percutaneous endoscopic techniques and catheterization for intravascular chemoembolization have led to increased incidence of pseudoaneurysmal degeneration of visceral vessels, in addition to the role played by arterial trauma after laparoscopic treatment of intraperitoneal and retroperitoneal diseases.¹²

With the dissemination of imaging techniques such as angio-CT and magnetic resonance angiography,

diagnoses of VAAs and VAPAs have increased, very often as incidental findings during examinations ordered for other abdominal diseases.¹⁰ The clinical presentation of these lesions is often vague and there are no clear signs to warn of imminent rupture. It is recommended that any suspected VAPA should be diagnosed and managed rapidly because of the high rates of rupture and hemorrhage.¹¹ Pitton et al.¹³

found that VAPAs are more likely to rupture than true aneurysms (76.3% vs. 3.1%, respectively).

It was therefore necessary to classify the lesion in order to decide whether to perform a procedure surgical

(open or catheter embolization) or adopt conservative follow-up.¹⁴ Conventional open techniques include resection with revascularization and ligation or final resection of the organ (generally splenectomy) and remain the gold standard treatment.^{8,15} However, they can very often cut off the blood flow in the principal artery and cause intestinal ischemia of varying degrees.¹⁴

Tulsyan et al.¹² demonstrated that conventional surgery can increase morbidity and mortality in cases with difficult to access sites, with technical difficulties, or with associated comorbidities that prevent vascular reconstruction, and in patients admitted in critical conditions (acute bleeding and rupture). They observed a 96% success rate for endovascular coil embolization.¹²

Certain limitations of open surgery make minimally invasive endovascular procedures an option for patients who are at greater risk from surgery.^{8,9,16} For hemodynamically stable patients, ET remains the first-choice option for known arterial bleeding and is considered safe and effective for treating VAPAs. One advantage of this type of approach is that it enables treatment to be tailored to different conditions, making the method more precise for reducing postoperative morbidity. Complications include rupture of the sac, ischemia distal of the pseudoaneurysm sac, and the

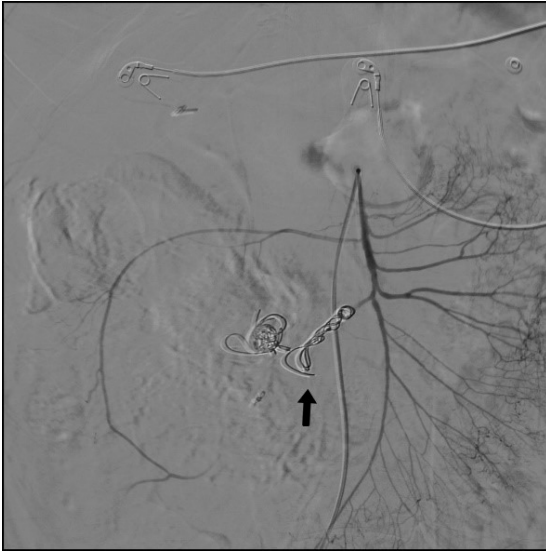

Figure 3. Control angiography after embolization of the ileocolic artery with microcoils, showing outflow and inflow sealed and no leakage (black arrow).

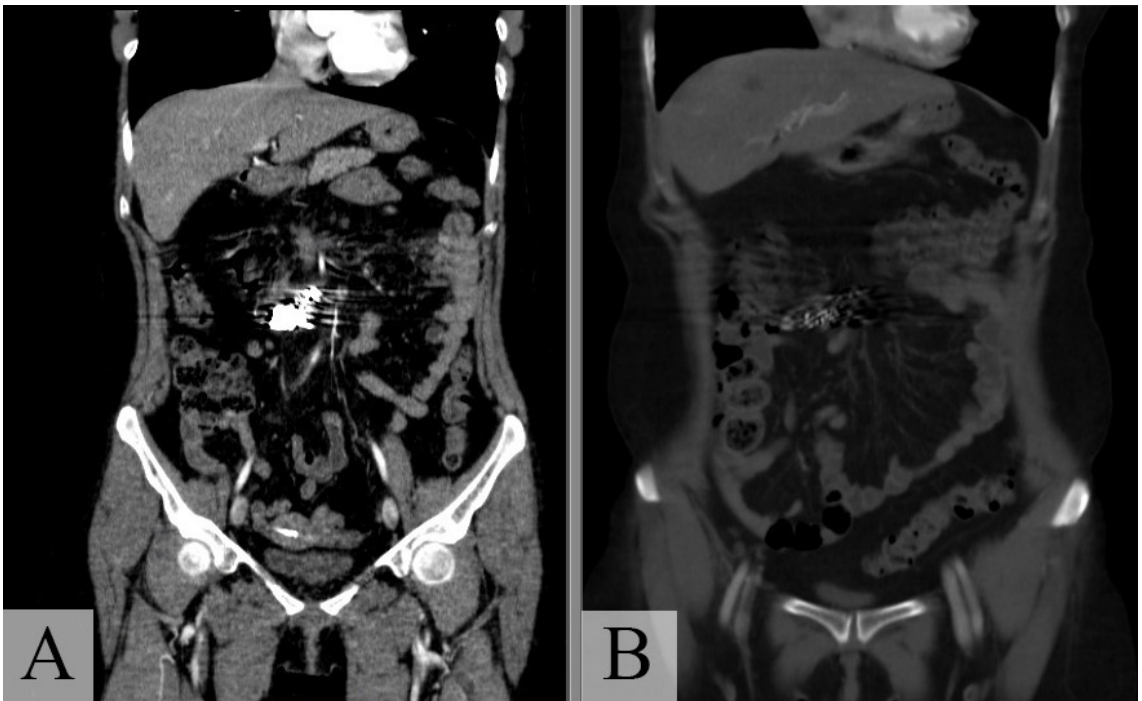


Figure 4. Control angiotomography 3 months after the procedure showing: **(A)** the microcoils positioned in the ileocolic artery and no leakage; **(B)** image of the entire abdomen, free from retroperitoneal hematoma.

possibility of arterial flow into the pseudoaneurysm if restoration of flow proves time-consuming (post-embolization syndrome).¹¹

A range of materials are available for occluding the artery, including coils, glues, detachable plugs, thrombin, gelfoam, detachable balloons, and embolization copolymer.^{11,17,18} One of the principal ET techniques is coil embolization of saccular aneurysms and VAPAs, without impeding the flow through the principal artery.¹⁴ Deployment of a flow-modulating stent is also a treatment option for fusiform aneurysms with large diameters and little tortuosity.¹⁴ When the aneurysmal ring is narrow, another option is catheter-guided embolization with coils, detachable or otherwise. The most recent types of coils are of particular interest. They are detachable, are made from platinum (which is a more malleable material), and are helical in shape.¹⁸

In the case described here, after angiography and selective catheterization of the ICA, the artery was embolized with microcoils to seal the aneurysm sac then Nester[®] platinum embolization coils (Cook Medical Inc., Indiana, United States) were released and controlled-release dacron fibers were deployed into the area of contrast leakage. The control angiography showed an absence of contrast leakage and preservation of the remaining arteries of the intestinal arch and the SMA. The coils described were chosen because of the compatibility they offer within the pseudoaneurysm sac, thereby averting any possible recanalization of the VAPA.¹⁸ In this case, endovascular treatment proved to be safe and satisfactory, with resolution of the patient's symptoms and early discharge on the 3rd postoperative day.

CONCLUSIONS

The case described illustrates the importance of early recognition and management of VAPAs with ET and coils, reducing morbidity and mortality in patients with acute abdomen secondary to hemorrhage of visceral arteries. Although this is a rare condition, similar situations to the one described are responsible for high lethality due to rupture and it is important to disseminate the technique and conduct in-depth studies of the subject. Long-term follow-up with larger numbers of patients will be needed to determine the final role of endoluminal treatment for visceral aneurysms and pseudoaneurysms.

REFERENCES

- Chiesa R, Astore D, Guzzo G, et al. Visceral artery aneurysms. *Ann Vasc Surg.* 2005;19(1):42-8. <http://dx.doi.org/10.1007/s10016-004-0150-2>. PMID:15714366.
- Moraes D Fo, Trevisan FB, Silvestre JMS, et al. Vascular ultrasonography for follow-up of endovascular repair of abdominal aorta aneurysms. *J Vasc Bras.* 2014;13(3):168-74. <http://dx.doi.org/10.1590/jvb.2014.019>.
- Azevedo FC, Zerati AE, Blasbalg R, Wolosker N, Puech-Leão P. Comparison of ultrasonography, computed tomography, and magnetic resonance imaging with intraoperative measurements in the evaluation of abdominal aortic aneurysms. *Clinics (São Paulo).* 2005;60(1):21-8. <http://dx.doi.org/10.1590/S1807-59322005000100006>. PMID:15838577.
- Sueyoshi E, Sakamoto I, Nakashima K, Minami K, Hayashi K. Visceral and peripheral arterial pseudoaneurysms. *AJR Am J Roentgenol.* 2005;185(3):741-9. <http://dx.doi.org/10.2214/ajr.185.3.01850741>. PMID:16120928.
- Pulli R, Dorigo W, Troisi N, Pratesi G, Innocenti AA, Pratesi C. Surgical treatment of visceral artery aneurysms: a 25-year experience. *J Vasc Surg.* 2008;48(2):334-42. <http://dx.doi.org/10.1016/j.jvs.2008.03.043>. PMID:18644480.
- Jesinger RA, Thoreson AA, Lamba R. Abdominal and pelvic aneurysms and pseudoaneurysms: imaging review with clinical, radiologic, and treatment correlation. *Radiographics.* 2013;33(3):E71-96. <http://dx.doi.org/10.1148/rg.333115036>. PMID:23674782.
- Roche-Nagle G, O'Donnell D, O'Hanrahan T. Visceral artery aneurysms: a symptomatic aneurysm of the ileocolic artery. *Vascular.* 2007;15(3):162-6. <http://dx.doi.org/10.2310/6670.2007.00020>. PMID:17573023.
- De Rosa A, Gomez D, Pollock JG, et al. The radiological management of pseudoaneurysms complicating pancreatitis. *JOP.* 2012;13(6):660-6. PMID:23183395.
- Taboada CR, Alonso JG, Cortés RP, Pelayo LV, Hernández PV, Sánchez FS. Dual endovascular repair (coils and stent) of a true aneurysm of the gastroduodenal artery. *J Vasc Bras.* 2020;19:e20190123. <http://dx.doi.org/10.1590/1677-5449.190123>. PMID:34178066.
- Shawky MS, Tan J, French R. Gastroduodenal Artery aneurysm: a case report and concise review of literature. *Ann Vasc Dis.* 2015;8(4):331-3. <http://dx.doi.org/10.3400/avd.cr.15-00086>. PMID:26730262.
- Saran M, Biswas S. A rare case of jejunal pseudoaneurysm presenting as acute small bowel obstruction after blunt trauma: discussion, management dilemmas, and a review of relevant literature. *Cureus.* 2019;11(9):e5655. <http://dx.doi.org/10.7759/cureus.5655>. PMID:31700756.
- Tulsyan N, Kashyap VS, Greenberg RK, et al. The endovascular management of visceral artery aneurysms and pseudoaneurysms. *J Vasc Surg.* 2007;45(2):276-83, discussion 283. <http://dx.doi.org/10.1016/j.jvs.2006.10.049>. PMID:17264002.
- Pitton MB, Dappa E, Jungmann F, et al. Visceral artery aneurysms: Incidence, management, and outcome analysis in a tertiary care center over one decade. *Eur Radiol.* 2015;25(7):2004-14. <http://dx.doi.org/10.1007/s00330-015-3599-1>. PMID:25693662.
- Ikeda O, Tamura Y, Nakasone Y, Iryou Y, Yamashita Y. Nonoperative management of unruptured visceral artery aneurysms: treatment by transcatheter coil embolization. *J Vasc Surg.* 2008;47(6):1212-9. <http://dx.doi.org/10.1016/j.jvs.2008.01.032>. PMID:18440188.
- Santos FS, Sousa KMDS, de Castro TAC, et al. Endovascular treatment of pseudoaneurysms secondary to chronic pancreatitis: reports of two cases. *J Vasc Bras.* 2018;17(1):71-5. <http://dx.doi.org/10.1590/1677-5449.012517>. PMID:29930685.
- Cely C, Stollman NH. Lupus abdominal crisis owing to rupture of an ileocolic aneurysm with successful angiographic treatment. *J Clin Gastroenterol.* 2001;32(4):347-50. <http://dx.doi.org/10.1097/00004836-200104000-00015>. PMID:11276282.

17. Gabelmann A, Görich J, Merkle EM. Endovascular treatment of visceral artery aneurysms. *J Endovasc Ther.* 2002;9(1):38-47. <http://dx.doi.org/10.1177/152660280200900108>. PMID:11958324.
18. Saad NE, Saad WE, Davies MG, Waldman DL, Fultz PJ, Rubens DJ. Pseudoaneurysms and the role of minimally invasive techniques in their management. *Radiographics.* 2005;25(Suppl 1):S173-89. <http://dx.doi.org/10.1148/rg.25si055503>. PMID:16227490.

Correspondence

Carolina Vasconcellos Sant'Anna
 Rua José Urias Fortes, 245, ap. 32, Bairro São Manoel
 CEP 15091-220 - São José do Rio Preto (SP), Brasil
 Tel.: +55 (11) 97654-5110
 E-mail: carolinavascsantanna@hotmail.com

Author information

CVS, FGK, VBF and MRC - 6th semester medical students, Faculdade de Medicina de São José do Rio Preto (FAMERP).
 AML – Physician, Universidade do Estado do Pará, Cirurgia Geral and Cirurgia Vasculare e Angiologia resident, Faculdade de Medicina de São José do Rio Preto (FAMERP).
 SROR - Physician, MSc in Ciências da Saúde, Faculdade de Medicina de São José do Rio Preto (FAMERP); Adjunct professor II-M, Serviço de Cirurgia Vasculare e Angiologia, Departamento de Cardiologia e Cirurgia Cardiovascular, FAMERP; Full member, Sociedade Brasileira de Angiologia e Cirurgia Vasculare (SBACV); Board certified in Angiologia e Cirurgia Vasculare, SBACV; Physician, Hospital de Base de São José do Rio Preto and Hospital Austa, São José do Rio Preto.
 ARM – Physician, Faculdade de Medicina de São José do Rio Preto (FAMERP), Hospital de Base de São José do Rio Preto; full member of Sociedade Brasileira de Angiologia e Cirurgia Vasculare (SBACV); Board certified in Angiologia e Cirurgia Vasculare, SBACV; Board certified in Angiorradiologia e Cirurgia Endovascular.
 VA - 5th semester medical student, Faculdade de Medicina de São José do Rio Preto (FAMERP).

Author contributions

Conception and design: CVS, FGK, AML, SROR, ARM, VBF
 Analysis and interpretation: CVS, FGK, AML, VBF, MRC
 Data collection: CVS, FGK, AML, VA, MRC
 Writing the article: CVS, FGK, AML, VA, SROR
 Critical revision of the article: AML, SROR, ARM
 Final approval of the article*: CVS, FGK, AML, SROR, ARM, VA, VBF, MRC
 Statistical analysis: N/A
 Overall responsibility: CVS, SROR

*All authors have read and approved of the final version of the article submitted to *J Vasc Bras.*