

Prolonged Doppler US-guided pneumatic compression of a radial artery pseudoaneurysm after percutaneous coronary intervention: a simple and effective solution for a rare and challenging problem

Compressão pneumática prolongada e guiada por ultrassom de um pseudoaneurisma da artéria radial após intervenção coronariana percutânea: solução simples e eficaz para um problema raro e desafiador

Marcos Danillo Oliveira¹ , Pedro Perillo¹, Lélío Lemos Neto¹, Adriano Caixeta¹

Abstract

Transradial access is associated with fewer access site-related complications, earlier patient mobilization, and greater postprocedural comfort. Pseudoaneurysms are an extremely rare complication after transradial procedures and the radial artery itself is the most atypical arterial site of occurrence. We report a case in which a non-surgical, non-invasive, simple, and effective solution (prolonged pneumatic compression) was used to manage a radial artery pseudoaneurysm, a very rare and challenging complication of transradial procedures.

Keywords: transradial access; complications; pseudoaneurysm; management; pneumatic compression.

Resumo

O acesso arterial transradial está associado a menos complicações relacionadas ao sítio de punção, com deambulação precoce do paciente e maior conforto pós-procedimento. O pseudoaneurisma é uma complicação extremamente rara após procedimentos transradiais, sendo a artéria radial, por si só, o sítio mais incomum para tal ocorrência. Relata-se um caso de um pseudoaneurisma de artéria radial, uma complicação rara e desafiadora, resolvido com êxito e de maneira simples, não invasiva e não cirúrgica (compressão pneumática prolongada).

Palavras-chave: acesso arterial transradial; complicações; pseudoaneurisma; manejo; compressão pneumática.

How to cite: Oliveira MD, Perillo P, Lemos Neto L, Caixeta A. Prolonged Doppler US-guided pneumatic compression of a radial artery pseudoaneurysm after percutaneous coronary intervention: a simple and effective solution for a rare and challenging problem. *J Vasc Bras.* 2023;22:e20210212. <https://doi.org/10.1590/1677-5449.202102122>

¹ Universidade Federal de São Paulo – UNIFESP, Escola Paulista de Medicina, Hospital Universitário I, São Paulo, SP, Brasil.

Financial support: None.

Conflicts of interest: No conflicts of interest declared concerning the publication of this article.

Submitted: January 25, 2022. Accepted: June 02, 2022.

The study was carried out at Hospital Universitário I, Escola Paulista de Medicina, Universidade Federal de São Paulo (UNIFESP), São Paulo, SP, Brazil.

Ethics committee approval: The Research Ethics Committee approved this study (decision number 4.071.731).



INTRODUCTION

Compared with the classic transfemoral access, transradial access has been shown to be cost-effective, with fewer access site-related complications, earlier patient mobilization, and greater postprocedural comfort. Although uncommon, it is still associated with some vascular complications: spasm, thrombotic occlusion, hematoma, pseudoaneurysm, arteriovenous fistula, and compartment syndrome.¹ We report herein a case in which a non-surgical, non-invasive, simple, and effective solution was used for management of a radial artery pseudoaneurysm, a very rare and challenging complication of transradial procedures.

The Research Ethics Committee approved this study (decision number 4.071.731).

CASE DESCRIPTION

A 50-year-old man with hypertension, diabetes, dyslipidemia, obesity, and an active smoking habit was referred to the cath lab due to stable angina in response to any minimal effort. Elective coronary angiography was uneventfully performed via right distal transradial access 6Fr, our default access site for routine coronary angiography and interventions.²⁻⁶ Severe ostial stenosis of the right posterior descending artery was found and elective percutaneous coronary intervention (PCI) was planned. A handmade hemostatic gauze pad was left

in situ for 30 minutes and completely removed after one hour, without bleeding. Proximal and distal radial artery (RA) pulses were palpable after hemostasis and at hospital discharge, 4h later, which was uneventful. One week later, the patient was brought back to the cath lab for the planned PCI. Despite palpable right distal RA pulse, it was not possible, after five successful punctures, to advance even a polymer-jacketed 0.0014" guidewire, probably due to distal RA thrombotic occlusion. It was decided to convert to proximal ipsilateral RA access. After prompt successful puncture, a 0.0014" guidewire was easily advanced up to the aortic root. Sudden, progressive, and painful forearm swelling developed, so RA perforation was suspected. Due to previous successful experiences with spontaneous sealing after sheath and catheter insertion,⁷ this strategy was adopted. During hydrophilic 6Fr sheath advancement, guidewire looping was noticed and easily unfolded (Supplementary Material Video 1) with wire manipulation and sheath advancement. The PCI was performed as planned. An angiogram during guiding catheter removal showed no evidence of any proximal radial artery perforation or any extravascular dye staining. A final sheath angiography confirmed right distal RA occlusion (Figure 1; Supplementary Material Video 2). Brachial, ulnar, and radial pulses were palpable, distal perfusion was preserved to all fingers, and the forearm swelling diminished. Proximal radial artery patent

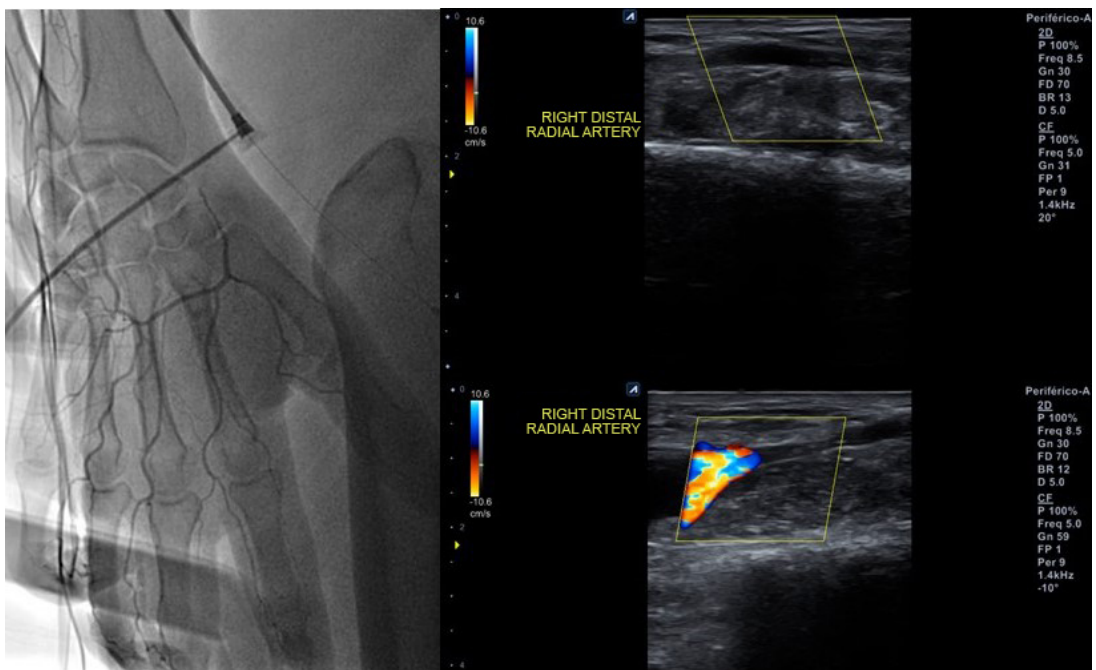


Figure 1. Right distal radial artery occlusion by angiography via proximal transradial sheath side port (left panel) and by post-procedure Doppler ultrasound (right panel).

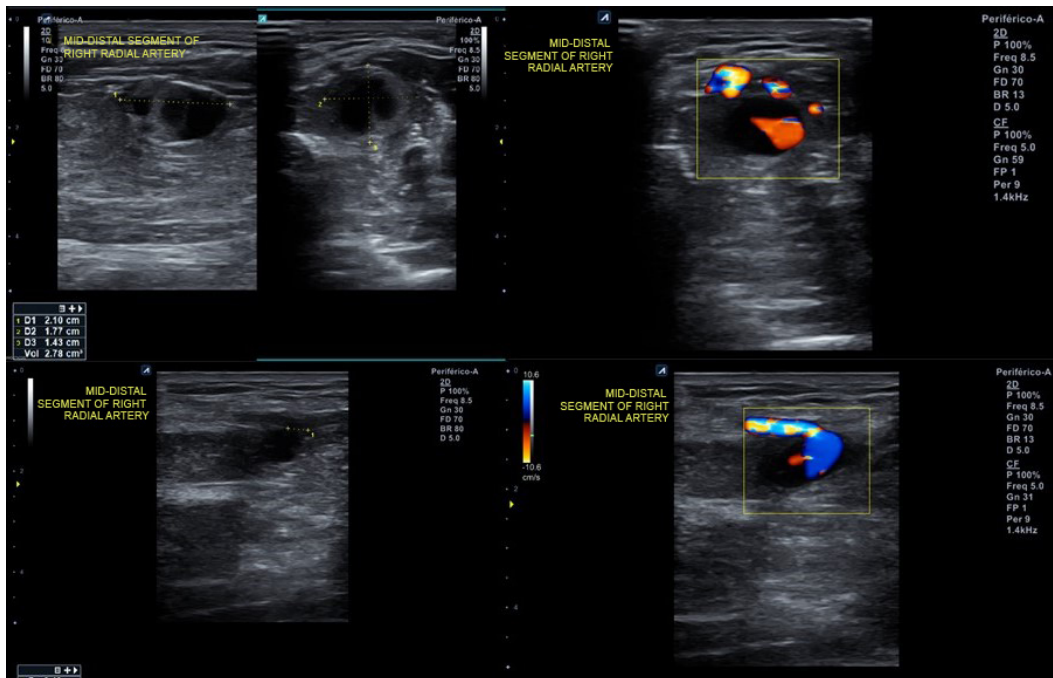


Figure 2. Post-procedure Doppler ultrasound evidenced proximal radial artery pseudoaneurysm.

hemostasis was performed with a hemostatic device. After removal, there was recrudescence of the painful forearm swelling. Doppler ultrasound (US) evidenced a 2.1 x 1.8 x 1.4cm (2.78cm³) pseudoaneurysm (Figure 2) with a 0.4cm neck. After continuous 30 min US-guided compression of the pseudoaneurysm neck (Figure 3), complete thrombotic occlusion was not achieved (Figure 4). Following precise neck location, a hemostatic device (TR BAND™ Radial Compression Device (Terumo Corp., Tokyo, Japan) was placed and inflated with 20mL of air (Figure 5), with maintenance of antegrade flow through the RA shown by Doppler US. After 4 hours uninterrupted compression, Doppler US showed proximal RA patency and thrombotic occlusion of the pseudoaneurysm (Figure 6). Physical examination (Figures 7, 8, and 9) and Doppler US follow-up (Figure 10) up to forty days after the index procedure corroborated complete resolution of the RA pseudoaneurysm.

DISCUSSION

Pseudoaneurysm is an extremely rare complication after transradial procedures, with a rate of occurrence of about 0.05%,⁸⁻⁹ while the RA itself is the most atypical arterial site of pseudoaneurysm occurrence.¹⁰ It is the result of inadequate thrombus formation after catheter/sheath removal, causing a hematoma that communicates with the arterial lumen. Risk factors

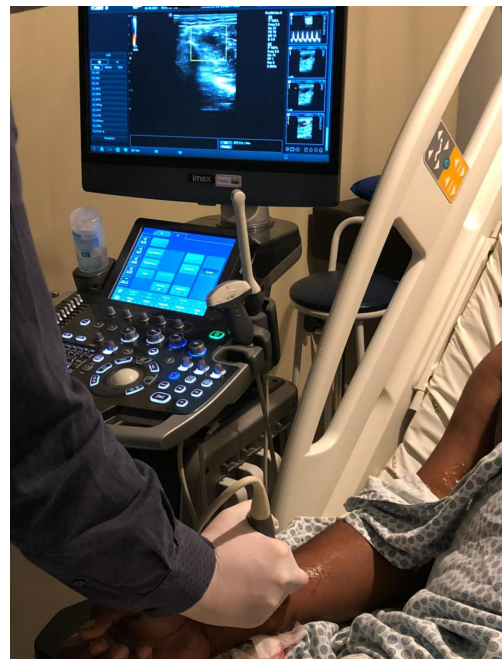

Figure 3. Doppler ultrasound-guided compression of pseudoaneurysm neck with probe.

are repeated arterial punctures, catheter infection, advanced age, longer procedural duration, coagulation disorders or anticoagulants/antiplatelet agents, large sheath diameter, and incomplete hemostasis.⁹⁻¹²

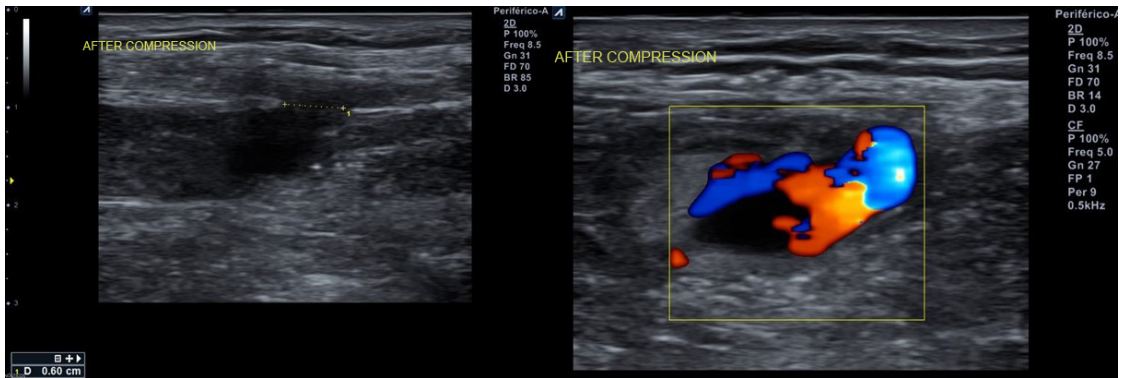


Figure 4. Doppler ultrasound after unsuccessful probe compression.

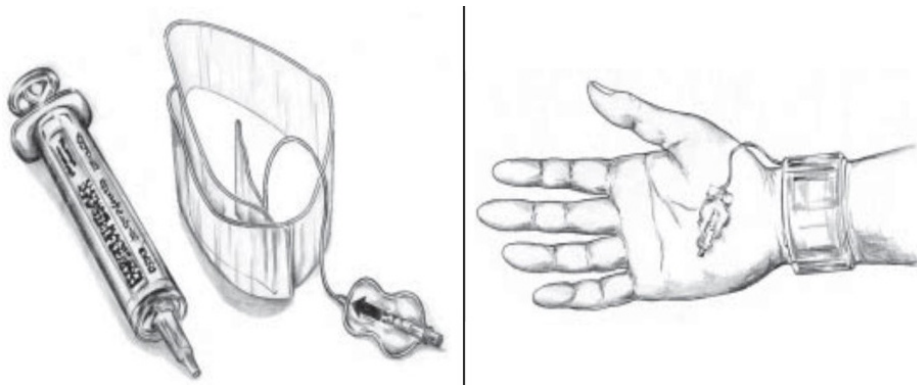


Figure 5. Hemostasis with the TR BAND™ Radial Compression Device (Terumo Corp., Tokyo, Japan).

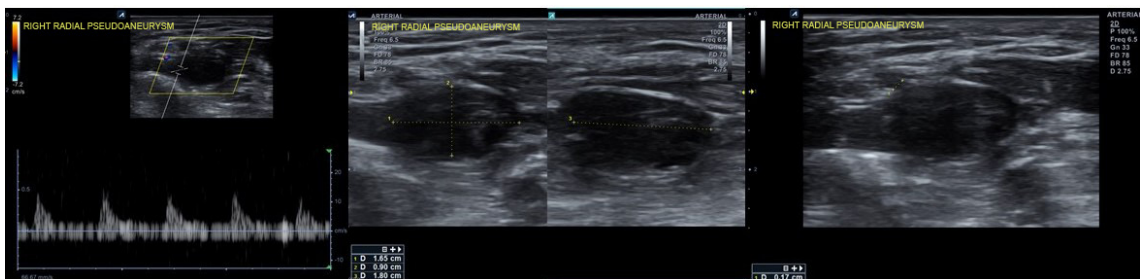


Figure 6. Doppler ultrasound confirmed thrombotic pseudoaneurysm occlusion after prolonged pneumatic neck compression.

The aim of radial pseudoaneurysm management is to repair the wall lesion and/or discontinue the flow communication between the artery and the hematoma.¹⁰ US-guided compression until occlusion is achieved can be performed and US-guided thrombin injection can also be undertaken, but fewer successful case reports exist for the RA.¹³⁻¹⁶ In addition, thrombin injection into the RA poses a significant risk of distal embolization and digital ischemia. This treatment has not been seriously considered. Surgical management is recommended in

patients with large pseudoaneurysms, or those that are symptomatic, expanding, infected, subacute, or when initial conservative management has failed.¹⁷

Oliveira et al.¹⁸ and Prejean et al.¹⁹ reported successful management of pseudoaneurysms after distal transradial access by prolonged Doppler US-guided neck compression with pneumatic devices. In both cases, thrombosis of the pseudoaneurysm was achieved and no further intervention was required, exactly like in the present case.

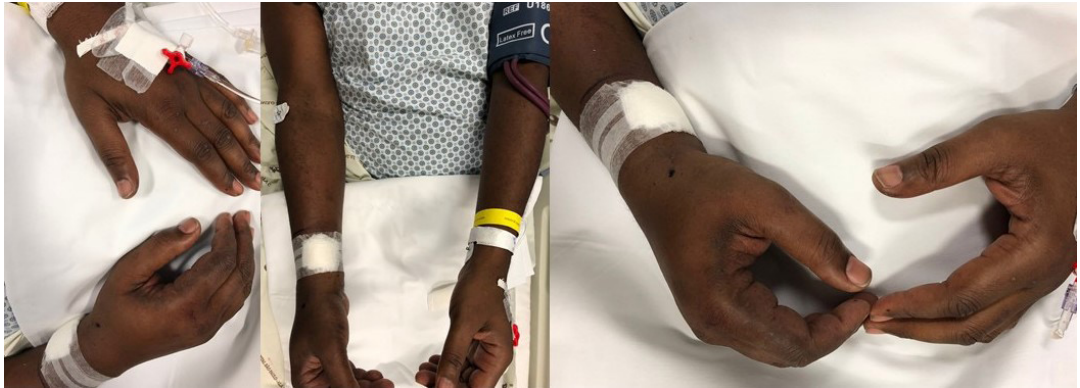

Figure 7. Physical appearance after prolonged pneumatic compression.

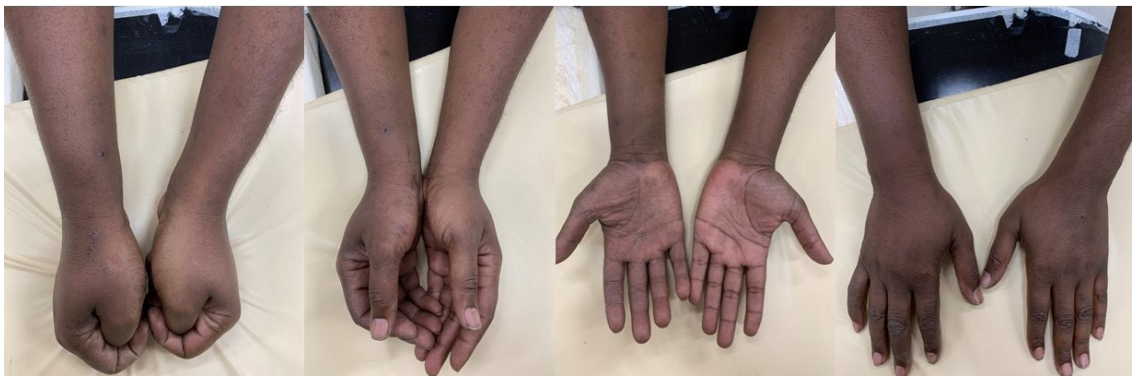

Figure 8. Physical appearance at seven-day follow-up.

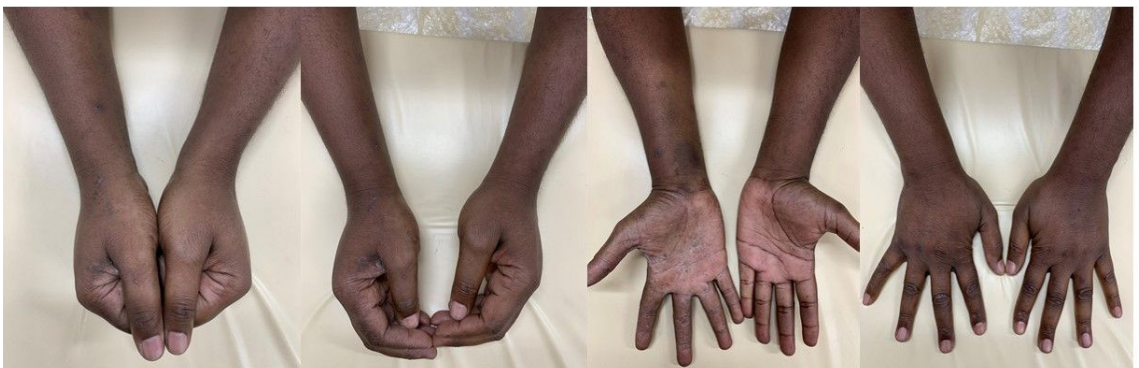

Figure 9. Physical appearance at forty-day follow-up.

Of note, an extensive literature review found no descriptions regarding the success rates of either of the aforementioned strategies or any specific relationships with ultrasonographic pseudoaneurysm features.

In conclusion, the present report suggests that, in this particular case, prolonged pneumatic compression

appeared to be promising for pseudoaneurysm management. Further prospective studies are needed in order to assure its efficacy and safety. Also, in case of acute thrombotic occlusion after distal transradial procedures, proximal ipsilateral transradial access is still a feasible option for future interventions.

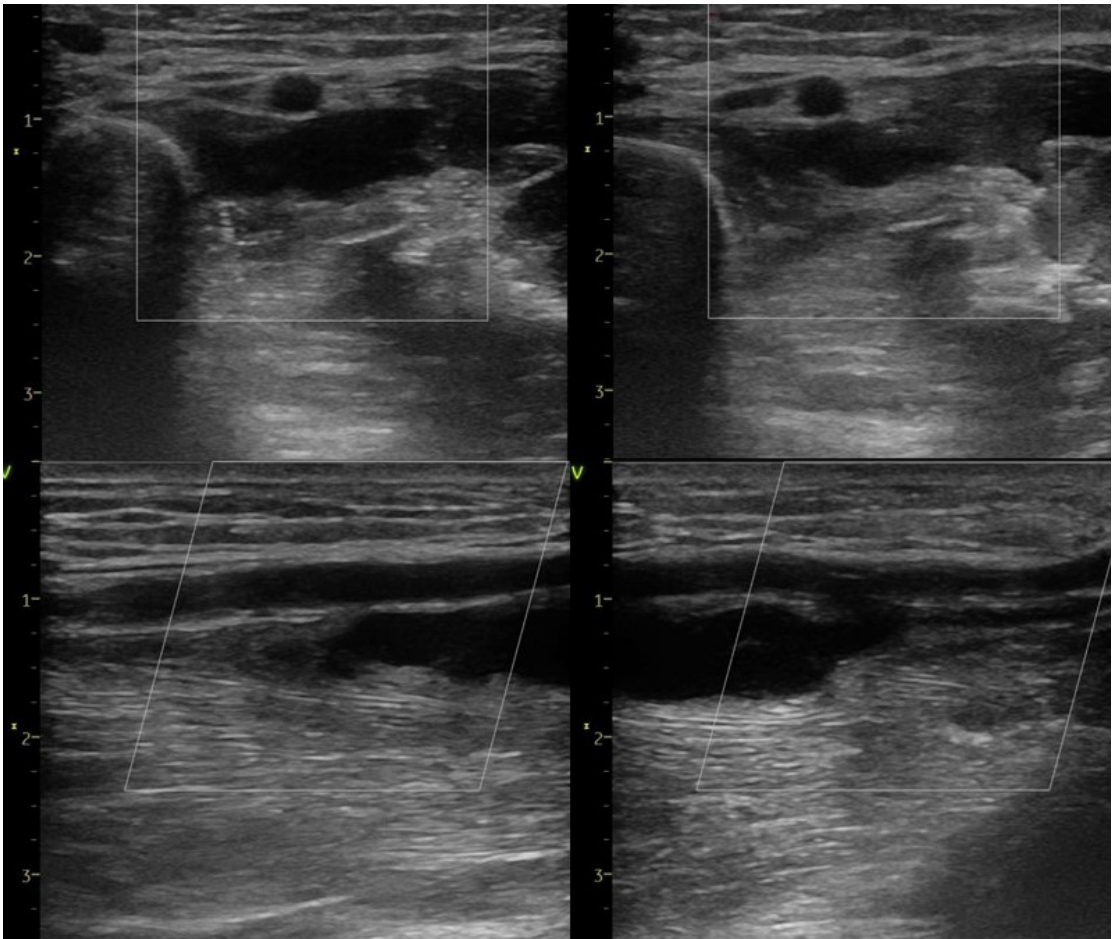


Figure 10. Doppler ultrasound confirmation of successful thrombotic pseudoaneurysm occlusion at forty-day follow-up.

REFERENCES

- Corcos T. Distal radial access for coronary angiography and percutaneous coronary intervention: a state-of-the-art review. *Catheter Cardiovasc Interv.* 2018;93(4):639-44. PMID:30536709.
- Oliveira MD, Navarro EC, Kiemeneij F. Distal transradial access as default approach for coronary angiography and interventions. *Cardiovasc Diagn Ther.* 2019;9(5):513-9. <http://dx.doi.org/10.21037/cdt.2019.09.06>. PMID:31737522.
- Oliveira MD, Caixeta A. Distal Transradial Access (dTRA) for coronary angiography and interventions: a quality improvement step forward? *J Invasive Cardiol.* 2020;32(9):E238-9. PMID:32865510.
- Oliveira MD, Navarro EC, Caixeta A. Distal transradial access for post-CABG coronary and surgical grafts angiography and interventions. *Indian Heart J.* 2021;73(4):440-5. <http://dx.doi.org/10.1016/j.ihj.2021.06.005>. PMID:34474755.
- Oliveira MD, Caixeta A. Distal transradial access for primary PCI in ST-segment elevation myocardial infarction. *JACC Cardiovasc Interv.* 2022;15(7):794-5. <http://dx.doi.org/10.1016/j.jcin.2022.02.021>. PMID:35393113.
- Oliveira MD, Navarro EC, Caixeta A. Distal transradial access for coronary procedures: a prospective cohort of 3,683 all-comers patients from the DISTRACTION registry. *Cardiovasc Diagn Ther.* 2022;12(2):208-19. <http://dx.doi.org/10.21037/cdt-21-542>. PMID:35433348.
- Oliveira MD, Barros TR, Caixeta A. Spontaneously sealed forearm radial artery perforation during a left distal transradial coronary intervention. *J Invasive Cardiol.* 2020;32(11):E303-4. PMID:33130601.
- Tatli E, Buturak A, Cakar A, et al. Unusual vascular complications associated with transradial coronary procedures among 10,324 patients: case based experience and treatment options. *J Interv Cardiol.* 2015;28(3):305-12. <http://dx.doi.org/10.1111/joic.12206>. PMID:25989895.
- Llácer Pérez M, González Jiménez JM, Jiménez Ruiz A. Pseudoaneurysm in the radial artery after catheterization. *Rev Esp Anestesiol Reanim.* 2006;53(2):119-21. PMID:16553346.
- Alerhand S, Apakama D, Nevel A, Nelson BP. Radial artery pseudoaneurysm diagnosed by point-of-care ultrasound five days after transradial catheterization: a case report. *World J Emerg Med.* 2018;9(3):223-6. <http://dx.doi.org/10.5847/wjem.j.1920-8642.2018.03.010>. PMID:29796148.
- Hamid T, Harper L, McDonald J. Radial artery pseudoaneurysm following coronary angiography in two octogenarians. *Exp Clin Cardiol.* 2012;17(4):260-2. PMID:23592950.
- Paxiuta J, Lobao MJ, Carvalho L. Radial artery pseudoaneurysm: rare complication of a frequent procedure. *BMJ Case Rep.*

- 2017;2017:bcr2016218313. <http://dx.doi.org/10.1136/bcr-2016-218313>. PMID:28073876.
13. Komorowska-Timek E, Teruya TH, Abou-Zamzam Jr AM, Papa D, Ballard JL. Treatment of radial and ulnar artery pseudoaneurysms using percutaneous thrombin injection. *J Hand Surg Am.* 2004;29(5):936-42. <http://dx.doi.org/10.1016/j.jhssa.2004.05.009>. PMID:15465248.
 14. Kang SS, Labropoulos N, Mansour MA, et al. Expanded indications for ultrasound-guided thrombin injection of pseudoaneurysms. *J Vasc Surg.* 2000;31(2):289-98. [http://dx.doi.org/10.1016/S0741-5214\(00\)90160-5](http://dx.doi.org/10.1016/S0741-5214(00)90160-5). PMID:10664498.
 15. Kleczynski P, Rakowski T, Dziewierz A, Jakala J, Dudek D. Ultrasound-guided thrombin injection in the treatment of iatrogenic arterial pseudoaneurysms: single-center experience. *J Clin Ultrasound.* 2014;42(1):24-6. <http://dx.doi.org/10.1002/jcu.22106>. PMID:24151057.
 16. Bauer P, Koshty A, Hamm CW, Gündüz D. Ultrasound guided percutaneous thrombin injection in a radial artery pseudoaneurysm following percutaneous coronary intervention. *Clin Res Cardiol.* 2014;103(12):1022-4. <http://dx.doi.org/10.1007/s00392-014-0744-9>. PMID:25049050.
 17. Provencher MT, Maurer C, Thompson M, Hofmeister E. Operative grafting of a pseudoaneurysm of the radial artery after a pediatric both-bone forearm fracture. *Orthopedics.* 2007;30(10):874-5. <http://dx.doi.org/10.3928/01477447-20071001-11>. PMID:17990416.
 18. Oliveira MD, Alves de Sá G, Navarro EC, Caixeta A. Pseudoaneurysm after distal transradial coronary intervention successfully managed by prolonged pneumatic compression: simple solution for a rare and challenging problem. *J Invasive Cardiol.* 2021;33(10):E836-8. PMID:34609331.
 19. Prejean SP, Von Mering G, Ahmed M. Successful treatment of pseudoaneurysm following left distal transradial cardiac catheterization with compression device. *Journal for Vascular Ultrasound.* 2019;43(2):81-5. <http://dx.doi.org/10.1177/1544316719844061>.

SUPPLEMENTARY MATERIAL

Supplementary material accompanies this paper.

Video 1. During hydrophilic 6Fr sheath advancement, guidewire looping was noted (inside the pseudoaneurysm cavity) and easily unfolded with wire manipulation and sheath advancement.

Video 2. Right distal radial artery occlusion by angiography via right proximal transradial sheath side port. This material is available as part of the online article from <https://doi.org/10.1590/1677-5449.202102122>

Correspondence

Adriano Caixeta
Escola Paulista de Medicina (UNIFESP), Hospital São Paulo,
Departamento de Cardiologia Intervencionista
Napoleão de Barros, nº 715, Vila Clementino
CEP 04024-002 - São Paulo (SP), Brasil
Tel.: +55 (11) 5576-4000
E-mail: acaixeta@me.com

Author information

MDPO - MSc in Cardiologia, Escola Paulista de Medicina, Universidade Federal de São Paulo (UNIFESP); preceptor, Programas de Residência Médica em Cardiologia e Hemodinâmica e Cardiologia Intervencionista, EPM-UNIFESP; COMPLEX PCI coordinator, Serviço de Hemodinâmica e Cardiologia Intervencionista, EPM-UNIFESP. PP - Interventional cardiologist, Escola Paulista de Medicina, Universidade Federal de São Paulo (UNIFESP).
LLPN - Cardiologist, Escola Paulista de Medicina, Universidade Federal de São Paulo (UNIFESP).
AC - Programa de Residência Médica, Hemodinâmica e Cardiologia Intervencionista; coordinator, Escola Paulista de Medicina, Universidade Federal de São Paulo (UNIFESP); chief, Serviço de Hemodinâmica e Cardiologia Intervencionista, EPM-UNIFESP.

Author contributions

Conception and design: MDO, PP, LLPN, AC
Analysis and interpretation: MDO, PP, LLPN, AC
Data collection: MDO, PP, LLPN, AC
Writing the article: MDO, PP, LLPN, AC
Critical revision of the article: MDO, PP, LLPN, AC
Final approval of the article*: MDO, PP, LLPN, AC
Statistical analysis: MDO, PP, LLPN, AC
Overall responsibility: MDO, PP, LLPN, AC

*All authors have read and approved of the final version of the article submitted to J Vasc Bras.